

EXERCISE 2**Organ Systems Overview****Time Allotment:** 1½ hours (rat dissection—1 hour; human torso model—½ hour).**Solutions:***Bleach Solution, 10%*

Measure out 100 milliliters of household bleach. Add water to a final volume of 1 liter.

**Multimedia Resources:** See Appendix B for Guide to Multimedia Resource Distributors.*Homeostasis* (FHS: 20 minutes, DVD, 3-year streaming webcast)*Homeostasis: The Body in Balance* (HRM: 26 minutes, DVD)*Practice Anatomy Lab™ 3.0 (PAL)* (PE: DVD, Website)**Laboratory Materials**

Ordering information is based on a lab size of 24 students, working in groups of 2 or 4. A list of supply house addresses appears in Appendix A.

Dissectible human torso model or cadaver	Disposable gloves, soap, and sponges	Twine or large dissecting pins
6–12 forceps	6–12 freshly killed or	6–12 dissecting trays
6–12 scissors	preserved rats, or	Lab disinfectant or 10%
6–12 blunt probes	predissected human	bleach
	cadaver	solution

Advance Preparation

1. Make arrangements for appropriate storage and disposal of dissection materials. Check with the Department of Health or the Department of Environmental Protection, or their counterparts, for state regulations.
2. Designate a disposal container for organic debris, set up a dishwashing area with hot soapy water and sponges, and provide lab disinfectant such as Wavicide-01 (Carolina) or a 10% bleach solution for washing down the lab benches.
3. Set out safety glasses and disposable gloves for dissection of freshly killed animals (to protect students from parasites) and for dissection of preserved animals.
4. Decide on the number of students in each dissecting group (a maximum of four is suggested; two is probably best). Each dissecting group should have a dissecting pan, dissecting pins, scissors, blunt probe, forceps, twine, and a preserved or freshly killed rat.

5. Preserved rats are more convenient to use unless small mammal facilities are available. If live rats are used, they may be killed a half-hour or so prior to the lab by administering an overdose of ether or chloroform. To do this, remove each rat from its cage and hold it firmly by the skin at the back of its neck. Put the rat in a container with cotton soaked in ether or chloroform. Seal the jar tightly, and wait until the rat ceases to breathe.
 6. Set out human torso models and a dissected human cadaver if available.
-

Comments and Pitfalls

1. Students may be overly enthusiastic when using the scalpel and cut away organs they are supposed to locate and identify. Have blunt probes available as the major dissecting tool, and suggest that the scalpel be used to cut only when everyone in the group agrees that the cut is correct.
 2. Be sure the lab is well ventilated, and encourage students to take fresh air breaks if the preservative fumes are strong. If the dissection animal will be used only once, it can be rinsed to remove most of the excess preservative.
 3. Organic debris may end up in the sinks, clogging the drains. Remind the students to dispose of all dissection materials in the designated container.
 4. The inferior vena cava and aorta may be difficult to distinguish in uninjected specimens.
-

Answers to Pre-Lab Quiz (p. 15)

- | | | |
|-------------|------------|--------------|
| 1. The cell | 3. nervous | 5. diaphragm |
| 2. c, organ | 4. urinary | |
-

Answers to Activity Questions

Activity 5: Examining the Human Torso Model (pp. 23–24)

2. From top to bottom, the organs pointed out on the torso model are: *brain, thyroid gland, trachea, lung, heart, diaphragm, liver, stomach, spleen, large intestine, greater omentum, small intestine*

3. Dorsal body cavity: *brain, spinal cord*

Thoracic cavity: *aortic arch, bronchi, descending aorta (thoracic region), esophagus, heart, inferior vena cava, lungs, trachea*

Abdominopelvic cavity: *adrenal gland, descending aorta (abdominal region), greater omentum, inferior vena cava, kidneys, large intestine, liver, pancreas, rectum, small intestine, spleen, stomach, ureters, urinary bladder*

Note: The diaphragm separates the thoracic cavity from the abdominopelvic cavity.

Right upper quadrant: *right adrenal gland, right kidney, large and small intestine, liver, pancreas, stomach, right ureter*

Left upper quadrant: *left adrenal gland, descending aorta, greater omentum, left kidney, large and small intestine, pancreas, spleen, stomach, left ureter*

Right lower quadrant: *large and small intestine, rectum, right ureter, urinary bladder*

Left lower quadrant: *descending aorta, greater omentum, large and small intestine, left ureter, urinary bladder*

4. Umbilical region: *small intestine, large intestine, greater omentum*

Epigastric region: *stomach, liver, small and large intestine, pancreas*

Hypogastric region: *small and large intestine (including rectum), urinary bladder*

Right iliac region: *large intestine, small intestine, greater omentum, right ureter*

Left iliac region: *large intestine, small intestine, greater omentum, left ureter*

Right lumbar region: *large and small intestine, right kidney, right adrenal gland, right ureter*

Left lumbar region: *large and small intestine, left kidney, left adrenal gland, left ureter*

Right hypochondriac region: *liver*

Left hypochondriac region: *stomach, spleen, pancreas*

Digestive: *esophagus, liver, stomach, pancreas, small intestine, large intestine (including rectum)*

Urinary: *kidneys, ureters, urinary bladder*

Cardiovascular: *aortic arch, heart, descending aorta, inferior vena cava*

Endocrine: *pancreas, adrenal gland, thyroid gland*

Reproductive: *none*

Respiratory: *lungs, bronchi, trachea*

Lymphatic/immune: *spleen*

Nervous: *brain, spinal cord*

Answer to Group Challenge: Odd Organ Out (p. 24)

Some possible answers to the questions are listed below. Student answers may vary.

1. Which is the “odd organ”?	Why is it the odd one out?
Stomach <u>Teeth</u> Small intestine Oral cavity	<i>The teeth are an accessory structure of the digestive system, whereas the oral cavity, stomach, and small intestine are part of the digestive tract.</i>
2. Which is the “odd organ”?	Why is it the odd one out?
<u>Thyroid gland</u> Thymus Spleen Lymph nodes	<i>The thyroid gland is not an organ of the lymphatic system.</i>

3. Which is the “odd organ”?	Why is it the odd one out?
Ovaries Prostate gland Uterus Uterine tubes	<i>The prostate gland is not part of the female reproductive system.</i>
4. Which is the “odd organ”?	Why is it the odd one out?
Stomach Small intestine Esophagus Large intestine	<i>The esophagus is in the thorax, whereas the stomach, small intestine, and large intestine are in the abdominopelvic cavity.</i>

REVIEW SHEET

EXERCISE 2

Organ Systems Overview

Name _____

Lab Time/Date _____

1. Use the key below to indicate which body systems perform the following functions. (Some responses are used more than once.) Then, circle the organ systems (in the key) that are present in all subdivisions of the ventral body cavity.

Key: a. cardiovascular d. integumentary g. nervous j. skeletal
b. digestive e. lymphatic/immune h. reproductive k. urinary
c. endocrine f. muscular i. respiratory

- | | |
|--|--|
| <u>k; urinary</u> | 1. rids the body of nitrogen-containing wastes |
| <u>c; endocrine</u> | 2. is affected by removal of the thyroid gland |
| <u>j; skeletal</u> | 3. provides support and the levers on which the muscular system acts |
| <u>a; cardiovascular</u> | 4. includes the heart |
| <u>d; integumentary</u> | 5. protects underlying organs from drying out and from mechanical damage |
| <u>e; lymphatic/immune</u> | 6. protects the body; destroys bacteria and tumor cells |
| <u>b; digestive</u> | 7. breaks down ingested food into its building blocks |
| <u>i; respiratory</u> | 8. removes carbon dioxide from the blood |
| <u>a; cardiovascular</u> | 9. delivers oxygen and nutrients to the tissues |
| <u>f; muscular</u> | 10. moves the limbs; facilitates facial expression |
| <u>k; urinary</u> | 11. regulates water balance and removes nitrogen-containing wastes from the body |
| <u>c; endocrine</u> and <u>h; reproductive</u> | 12. facilitate conception and childbearing |
| <u>c; endocrine</u> | 13. controls the body by means of chemical molecules called hormones |
| <u>d; integumentary</u> | 14. is damaged when you cut your finger or get a severe sunburn |

2. Using the key above, choose the *organ system* to which each of the following sets of organs or body structures belongs.

<u>e; lymphatic/immune</u>	1. thymus, spleen, lymphatic vessels	<u>d; integumentary</u>	5. epidermis, dermis, cutaneous sense organs
<u>j; skeletal</u>	2. bones, cartilages, tendons	<u>h; reproductive</u>	6. testis, ductus deferens, urethra
<u>c; endocrine</u>	3. pancreas, pituitary, adrenal glands	<u>b; digestive</u>	7. esophagus, large intestine, rectum
<u>i; respiratory</u>	4. trachea, bronchi, lungs	<u>f; muscular</u>	8. muscles of the thigh, postural muscles

3. Using the key, place the following organs in their proper body cavity. Letters may be used more than once.

Key: a. abdominopelvic b. cranial c. spinal d. thoracic

<u>a; abdominopelvic</u>	1. stomach	<u>a; abdominopelvic</u>	4. liver	<u>d; thoracic</u>	7. heart
<u>d; thoracic</u>	2. esophagus	<u>c; spinal</u>	5. spinal cord	<u>d; thoracic</u>	8. trachea
<u>a; abdominopelvic</u>	3. large intestine	<u>a; abdominopelvic</u>	6. urinary bladder		
<u>a; abdominopelvic</u>	9. rectum				

4. Using the organs listed in question 3 above, record, by number, which would be found in the abdominopelvic regions listed below.

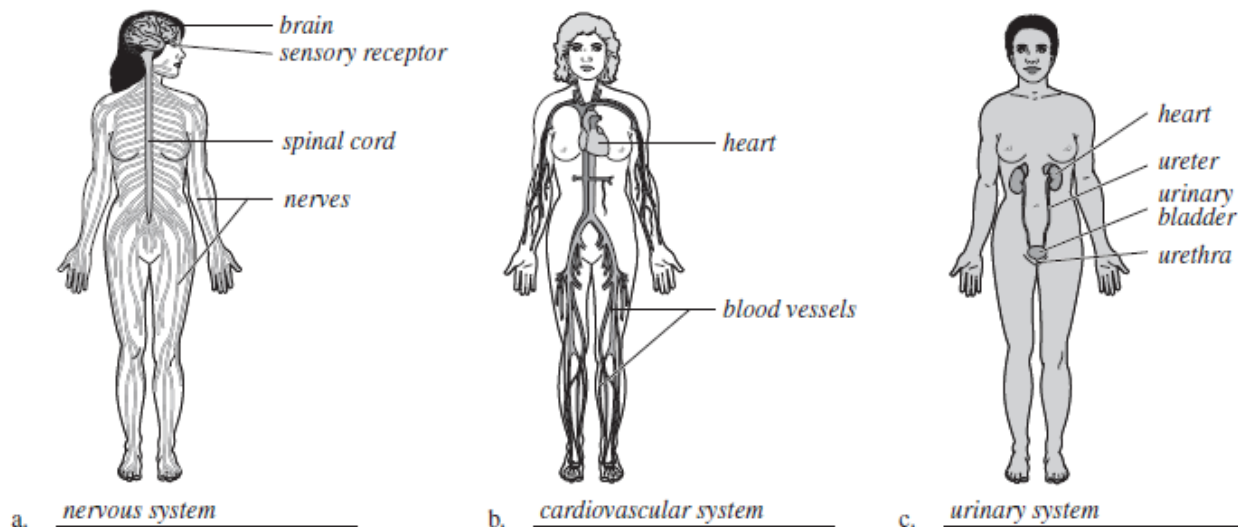
<u>3, 6, 9</u>	1. hypogastric region	<u>1, 3, 4</u>	4. epigastric region
<u>3</u>	2. right lumbar region	<u>1</u>	5. left iliac region
<u>3</u>	3. umbilical region	<u>1, 3</u>	6. left hypochondriac region

5. The levels of organization of a living body include cell, tissue, organ, organ system, and organism.

6. Define *organ*. A body part (or structure) that is made up of two or more tissue types and performs a specific body function, e.g., the stomach, the kidney

7. Using the terms provided, correctly identify all of the body organs indicated with leader lines in the drawings below. Then name the organ systems by entering the name of each on the answer blank below each drawing.

Key: blood vessels heart nerves spinal cord urethra
 brain kidney sensory receptor ureter urinary bladder



8. Why is it helpful to study the external and internal structures of the rat? Many of the external and internal structures are similar to those in the human.
- Studying the rat can help you to understand your own structure.