

Chapter 02: The Tooth: Functions and Terms

Brand/Isselhard: Anatomy of Orofacial Structures, 8th Edition

MULTIPLE CHOICE

1. The sensation of pain is felt in which part of the tooth?
 - a. Enamel
 - b. Dentin
 - c. Cementum
 - d. Pulp

ANS: D

The dental pulp is the sensory and nourishing portion of the tooth. It is composed of blood vessels, lymph vessels, connective tissue, and nerve cells. The pulp also contains special dentin-reparative/formative cells called odontoblasts. Sensation of pain is not felt in enamel, cementum, or dentin.

REF: pp. 15-17 OBJ: To identify the different tissues that compose teeth

NAT: CDA: GC I.A.7. Identify basic oral and dental anatomy, physiology, and development, including but not limited to: teeth. TOP: BLOOM: Remembering

2. Each of the following terms refers to an “in-between” surface EXCEPT one. Which one is the EXCEPTION?
 - a. Facial
 - b. Mesial
 - c. Distal
 - d. Proximal

ANS: A

Proximal, mesial, and distal are terms that describe surfaces of teeth that face a neighboring tooth; they also can be thought of as “in-between” surfaces. Proximal is the more general term for this type of surface. More specifically, a mesial surface is the proximal surface of a tooth closest to the midline; distal describes the proximal surface farthest from the midline. Facial surfaces are NOT proximal surfaces. Facial surfaces are more specifically known as labial (lip) surfaces on anterior teeth or buccal surfaces on posterior teeth.

REF: p. 19 OBJ: To define the terminology used in naming the landmarks of teeth

NAT: CDA: GC I.A.7. Identify basic oral and dental anatomy, physiology, and development, including but not limited to: teeth. | CDA: GC I.C.2. Identify the surfaces of the tooth.

TOP: BLOOM: Remembering

3. Which of the following is an example of a line angle?
 - a. Mesiolabioincisal
 - b. Buccolingual
 - c. Mesiodistal
 - d. Labioincisal
 - e. Inciso-occlusal

ANS: D

Only the labioincisal description qualifies as a line angle because line angles separate two adjacent surfaces of a tooth by forming a junction. The labioincisal line angle represents the junction of the labial surface of an anterior tooth with its incisal edge; note these are two adjacent surfaces on anterior teeth. Buccolingual, inciso-occlusal, and mesiodistal junctions are not adjacent surfaces. A mesiolabioincisal line angle is not a line angle because it represents the junction of three adjacent surfaces and is thus a point angle.

REF: pp. 17-19 OBJ: To name and identify the line angles of teeth

NAT: CDA: GC I.A.7. Identify basic oral and dental anatomy, physiology, and development, including but not limited to: teeth. TOP: BLOOM: Remembering

4. The hard yellow tissue that makes up the bulk of the tooth is called the
- enamel
 - dentin
 - cementum
 - pulp

ANS: B

Dentin is the hard, dense, calcified tissue that forms the greatest bulk of the tooth because it forms the largest portion of the crown and root. Softer than enamel, but harder than cementum or bone, the chemical composition of dentin is 70% inorganic and 30% organic matter and water. Unlike enamel, dentin is capable of adding to itself by producing reparative dentin.

REF: p. 14 OBJ: To identify the different tissues that compose teeth

NAT: CDA: GC I.A.7. Identify basic oral and dental anatomy, physiology, and development, including but not limited to: teeth. TOP: BLOOM: Remembering

5. All of the following formations are depressions EXCEPT one. Which one is the EXCEPTION?
- Fossa
 - Marginal ridge
 - Developmental groove
 - Lingual pit
 - All of the above are depressions.

ANS: B

A ridge is an elevated portion of a tooth that runs in a line and is named for the specific location in which it occurs. Specifically, marginal ridges are the rounded borders of enamel that form the mesial and distal elevated shoulders of the occlusal surfaces of posterior teeth as well as the mesial and distal shoulders of the lingual surfaces of anterior teeth.

Fossae, grooves, and pits are depressed formations within the tooth. They are also described as concavities, indented areas, or simply concave structures. A fossa is broadly defined as a depression or concavity. Developmental grooves are shallow, depressed lines that separate primary parts of the crown or root. A pit is a pinhole evident within a fossa or anywhere on a tooth. A lingual pit occurs on the lingual surface of a tooth.

REF: pp. 21-24 OBJ: To name and identify the location of the various tooth surfaces

NAT: CDA: GC I.A.7. Identify basic oral and dental anatomy, physiology, and development, including but not limited to: teeth. TOP: BLOOM: Remembering

6. The function of both incisors and premolars is to cut food. The function of molars is to cut, grind, and chew food.
- Both statements are true.
 - The first statement is true; the second statement is false.
 - The first statement is false; the second statement is true.
 - Both statements are false.

ANS: D

Both statements contain incorrect information. While it is true that the function of incisors is to tear food, premolars are more like molars; their pointed buccal cusps hold food while the lingual cusps grind it. Regarding the second statement, the function of molars is to grind and chew food; tearing or incising is NOT a molar function.

REF: pp. 17-18

OBJ: To understand the individual functions and therefore the individual differences that exist among incisors, canines, premolars, and molars

NAT: CDA: GC I.A.7. Identify basic oral and dental anatomy, physiology, and development, including but not limited to: teeth. TOP: BLOOM: Remembering

7. The CEJ is where enamel meets the
- dentin
 - junction
 - cementum
 - cervical third

ANS: C

Enamel and cementum meet at the cemento-enamel junction (CEJ). The demarcating line is called the cervical line, formed by the junction of the cementum of the root and enamel of the crown.

REF: pp. 11-12 OBJ: To differentiate between clinical and anatomic crowns and roots

NAT: CDA: GC I.A.7. Identify basic oral and dental anatomy, physiology, and development, including but not limited to: teeth. TOP: BLOOM: Remembering

8. The dental tissue that most resembles bone is
- cementum
 - dentin
 - enamel
 - none of the above

ANS: A

Cementum, a bonelike substance, contains 45% to 50% inorganic and 50% to 55% organic matter. Not as dense or as hard as enamel or dentin, cementum is more dense than bone and physiologically resembles bone. Cementum covers the root and provides a medium for the attachment of the tooth to the alveolar bone.

REF: p. 16 OBJ: To identify the different tissues that compose teeth

NAT: CDA: GC I.A.7. Identify basic oral and dental anatomy, physiology, and development, including but not limited to: teeth. TOP: BLOOM: Remembering

9. How many surfaces does a posterior tooth have?

- a. 2
- b. 3
- c. 4
- d. 5
- e. 6

ANS: D

Posterior teeth have five surfaces whereas anterior teeth have four surfaces and a ridge. Posterior surfaces are mesial, distal, buccal, lingual, and occlusal. Anterior tooth surfaces are mesial, distal, facial, lingual, and a biting surface is called an incisal ridge. Experts are in disagreement as to whether the incisal ridge of anterior teeth qualifies as a fifth surface.

REF: p. 19

OBJ: To name and identify the location of the various tooth surfaces

NAT: CDA: GC I.A.7. Identify basic oral and dental anatomy, physiology, and development, including but not limited to: teeth. | CDA: GC I.C.2. Identify the surfaces of the tooth.

TOP: BLOOM: Remembering

10. None of the following tissues have the ability to regenerate EXCEPT one. Which one is the EXCEPTION?
- a. Enamel
 - b. Dentin
 - c. Pulp
 - d. Periodontal ligament

ANS: B

Dentin has the unique ability to regenerate, or stated differently, to add to itself. The resultant material, called secondary dentin, is formed throughout the pulp chamber after tooth eruption. Over time, secondary dentin can completely fill the pulp chamber and become problematic. A specific type of secondary dentin called reparative dentin is laid down in response to dental caries or trauma. Please note that while not a selection in this question, cellular cementum, which is confined to the apical third of the root, can reproduce to compensate for attrition of more coronal aspects of a tooth.

REF: p. 14

OBJ: To identify the different tissues that compose teeth

NAT: CDA: GC I.A.7. Identify basic oral and dental anatomy, physiology, and development, including but not limited to: teeth.

TOP: BLOOM: Remembering

11. Pulp canals
- a. are located in the crown portion
 - b. have hornlike projections
 - c. occupy the root portion
 - d. occupy both the crown and root portion

ANS: C

Anatomically the pulp is divided into two areas: the pulp chamber and the pulp canals. The pulp canals, also called root canals, are located within the roots of the tooth. The pulp chamber is located within the coronal portion of the tooth. Together the pulp chamber and pulp canals are referred to as the pulp cavity. Hornlike projections, appropriately called the pulp horns, are located at the most coronal aspect of the pulp cavity.

REF: p. 17

OBJ: To identify the different tissues that compose teeth

NAT: CDA: GC I.A.7. Identify basic oral and dental anatomy, physiology, and development,

including but not limited to: teeth.

TOP: BLOOM: Remembering

12. The tooth surface facing the lip is called the mesial surface. The corresponding surface facing the cheek is called the distal surface.
- Both statements are true.
 - The first statement is true; the second statement is false.
 - The first statement is false; the second statement is true.
 - Both statements are false.

ANS: D

The key feature to this terminology is the position of a surface within the arch. Surfaces of anterior teeth that face the lip are called labial surfaces. Surfaces of posterior teeth that face the cheek are called buccal surfaces. A more broad term, encompassing both labial and buccal surfaces, is the facial surface. Mesial and distal surfaces are considered proximal surfaces and are adjacent, next to, or face neighboring teeth. Mesial proximal surfaces face to the midline while distal proximal surfaces face away from the midline.

REF: p. 19

OBJ: To name and identify the location of the various tooth surfaces

NAT: CDA: GC I.A.7. Identify basic oral and dental anatomy, physiology, and development, including but not limited to: teeth. | CDA: GC I.C.2. Identify the surfaces of the tooth.

TOP: BLOOM: Remembering

13. The prominence on the cervical third of the lingual aspect of anterior teeth is called the
- cervical line
 - lingual ridge
 - marginal ridge
 - cingulum
 - lingual cusp

ANS: D

The cingulum is the developmental lobe that makes up the bulk of the cervical third of anterior teeth. The lingually occurring cingulum is considered the fourth lobe of anterior teeth because anterior teeth are comprised of three other lobes, all positioned on the labial surface. The cervical line is the line that demarcates the cemento-enamel junction (CEJ). A lingual ridge is the triangular ridge of a mesiobuccal cusp that runs to the center of an occlusal surface. A marginal ridge is a rounded border of enamel that forms the mesial and distal shoulders of occlusal surfaces of posterior teeth and the mesial and distal shoulders of the lingual surfaces of anterior teeth. Cusps occur on canines, premolars, and molars. Lingual cusps are positioned at the lingual aspect of teeth and assist in chewing and grinding functions.

REF: p. 2 | p. 12 | p. 19 | p. 21

OBJ: To name and identify the location of the various tooth surfaces

NAT: CDA: GC I.A.7. Identify basic oral and dental anatomy, physiology, and development, including but not limited to: teeth.

TOP: BLOOM: Remembering

14. Each of the following teeth is developed from four lobes EXCEPT one. Which one is the EXCEPTION?
- Maxillary incisor
 - Mandibular canine
 - Maxillary first molar

d. Mandibular second molar

ANS: C

Incisors, canines, and most premolars are developed from four lobes—three facial and one lingual. Second molars are developed from four lobes—two facial and two lingual. First molars develop from five lobes.

REF: p. 21

OBJ: To recognize how the functions of teeth determine their shape and size

NAT: CDA: GC I.A.7. Identify basic oral and dental anatomy, physiology, and development, including but not limited to: teeth.

TOP: BLOOM: Remembering

15. In a partially erupted tooth, the visible portion is called the clinical crown. The anatomic crown is not yet fully formed.
- Both statements are true.
 - The first statement is true; the second statement is false.
 - The first statement is false; the second statement is true.
 - Both statements are false.

ANS: B

The clinical crown is the portion of the tooth that is actually visible in the mouth. In a partially erupted tooth only the visible portion, i.e., the portion coronal to the marginal gingiva, comprises the clinical crown. Conversely, in areas of gingival recession the entire portion of the tooth that is visible, i.e., coronal to the marginal gingiva, comprises the clinical crown. In cases of recession the visible portion of the root as well as the entire crown comprise the clinical crown. The second statement is false because in partially erupted teeth the crown is fully formed.

REF: p. 11

OBJ: To differentiate between clinical and anatomic crowns and roots

NAT: CDA: GC I.A.7. Identify basic oral and dental anatomy, physiology, and development, including but not limited to: teeth.

TOP: BLOOM: Remembering

16. Which dental tissue is composed of 70% inorganic and 30% organic matter?
- Dentin
 - Enamel
 - Cementum
 - Bone

ANS: A

The chemical composition of dentin is 70% inorganic and 30% organic matter and water. Dentin is softer than enamel but harder than cementum or bone. Dentin, the tissue forming the greatest bulk of the tooth, is yellow in color and elastic in nature. It is wrapped in an envelope of enamel covering the crown and an envelope of cementum covering the tooth.

REF: p. 14

OBJ: To identify the different tissues that compose teeth

NAT: CDA: GC I.A.7. Identify basic oral and dental anatomy, physiology, and development, including but not limited to: teeth.

TOP: BLOOM: Remembering

17. Which structure separates primary parts of a crown or root?
- Marginal ridge
 - Developmental groove
 - Developmental pit

- d. Transverse ridge
- e. B and C

ANS: B

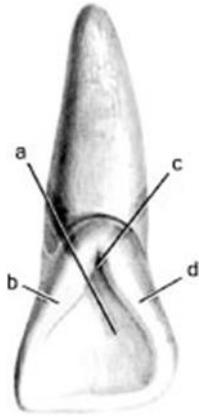
Shallow grooves or lines that separate primary parts of the crown or root are called developmental grooves. Marginal ridges are rounded borders of enamel that form mesial and distal shoulders of occlusal and incisal surfaces. Developmental pits are pinpoint holes evident within a fossa or anywhere on a tooth that are not associated with a disease process. A transverse ridge is the union of two triangular ridges, a buccal and a lingual, that cross the occlusal surface of a posterior tooth.

REF: p. 21 | pp. 25-26

OBJ: To differentiate between clinical and anatomic crowns and roots

NAT: CDA: GC I.A.7. Identify basic oral and dental anatomy, physiology, and development, including but not limited to: teeth. TOP: BLOOM: Remembering

18. In the illustration below, structure “a” represents the



- a. distal marginal ridge
- b. mesial marginal ridge
- c. lingual fossa
- d. lingual groove

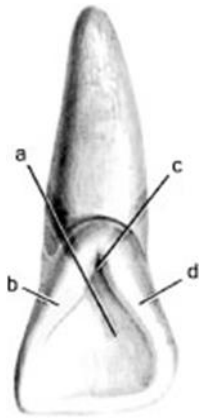
ANS: C

Structure “a” in the illustration is the lingual fossa. A fossa is a depression, concavity, or an area on the tooth that is indented. Fossae are named for their location; the fossa represented in the question is a lingual fossa. Structures b, c, and d are the mesial marginal ridge, the lingual groove, and the distal marginal ridge, respectively.

REF: p. 21 | p. 23 OBJ: To name and identify the location of the various tooth surfaces

NAT: CDA: GC I.A.7. Identify basic oral and dental anatomy, physiology, and development, including but not limited to: teeth. TOP: BLOOM: Remembering

19. In the illustration below, structure “b” is the



- a. distal marginal ridge
- b. mesial marginal ridge
- c. lingual fossa
- d. lingual groove

ANS: B

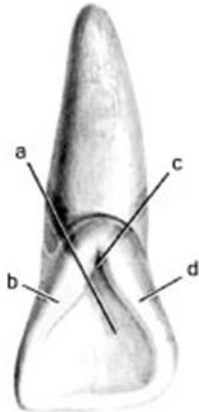
Structure “b” in the illustration is the mesial marginal ridge, which forms the mesial shoulder of the lingual surface of an anterior tooth. Structures a, c, and d are the lingual fossa, the lingual groove, and the distal marginal ridge, respectively.

REF: p. 21 | pp. 23-24

OBJ: To name and identify the location of the various tooth surfaces

NAT: CDA: GC I.A.7. Identify basic oral and dental anatomy, physiology, and development, including but not limited to: teeth. TOP: BLOOM: Remembering

20. In the illustration below, structure “c” is the



- a. distal marginal ridge
- b. mesial marginal ridge
- c. lingual fossa
- d. lingual groove

ANS: D

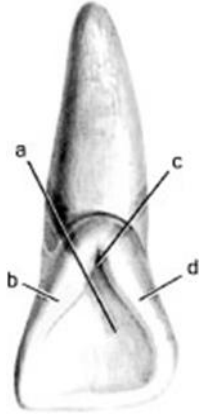
Structure “c” in the illustration is the lingual groove, which is a developmental line that separates the fourth (labial) lobe from the three labial lobes of anterior tooth. Structures a, b, and d, are the lingual fossa, the mesial marginal ridge, and the distal marginal ridge, respectively.

REF: p. 25

OBJ: To name and identify the location of the various tooth surfaces

NAT: CDA: GC I.A.7. Identify basic oral and dental anatomy, physiology, and development, including but not limited to: teeth. TOP: BLOOM: Remembering

21. In the illustration below, structure “d” is the



- a. distal marginal ridge
- b. mesial marginal ridge
- c. lingual fossa
- d. lingual groove

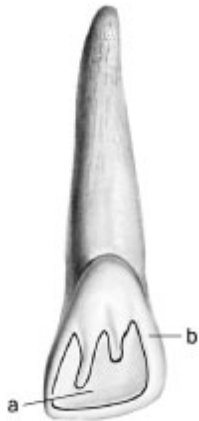ANS: A

Structure “d” in the illustration is the distal marginal ridge, which forms the distal shoulder of the lingual surface of an anterior tooth. Structures a, b, and c are the lingual fossa, mesial marginal ridge, and the lingual groove, respectively.

REF: p. 21 | p. 23 OBJ: To name and identify the location of the various tooth surfaces

NAT: CDA: GC I.A.7. Identify basic oral and dental anatomy, physiology, and development, including but not limited to: teeth. TOP: BLOOM: Remembering

22. In the following illustration, structure “a” refers to a fossa, which is a convexity or bulge on a tooth. Structure “b” refers to a ridge, which is a concavity or depression within a tooth.



- a. Both statements are true.
- b. The first statement is true; the second statement is false.
- c. The first statement is false; the second statement is true.
- d. Both statement are false.

ANS: D

Although the structures are correctly identified, the descriptive comments are reversed so both statements are incorrect. A fossa is a concavity or depression within a tooth. A ridge is a convexity or bulge on a tooth. More specifically, “a” is the lingual fossa; “b” is the distal marginal ridge.

REF: p. 21 OBJ: To name and identify the location of the various tooth surfaces
NAT: CDA: GC I.A.7. Identify basic oral and dental anatomy, physiology, and development, including but not limited to: teeth. TOP: BLOOM: Remembering

MULTIPLE RESPONSE

1. The pulp is composed of which of the following tissues (*Select all that apply.*)?
 - a. Lymph tissue
 - b. Connective tissue
 - c. Nerve tissue
 - d. Odontoblasts
 - e. Alveolus

ANS: A, B, C, D

The pulp is composed of blood vessels, lymph vessels, connective tissue, nerve tissue, and special dentin-formative cells called odontoblasts. Alveolus, the term for the tooth socket within the alveolar process, is not contained within the pulp and is an incorrect response.

REF: p. 13 | p. 16 OBJ: To identify the different tissues that compose teeth
NAT: CDA: GC I.A.7. Identify basic oral and dental anatomy, physiology, and development, including but not limited to: teeth. TOP: BLOOM: Remembering

2. Which of the following structures represent a concavity or depression within the surface of a tooth (*Select all that apply.*)?
 - a. Pit
 - b. Fossa
 - c. Tubercle
 - d. Cusp
 - e. Groove

ANS: A, B, E

A concavity is a carved-out section or area, like a cave. The smallest concavities found on teeth are called pits, which are pinpoint holes usually occurring along developmental grooves or fossa. Grooves and fossa are also concavities because they are depressed or carved-out areas. Conversely, tubercles and cusps represent the opposite of concavities, convexities. A convexity is defined as an area that bulges out.

REF: p. 21 | p. 25 OBJ: To name and identify the location of the various tooth surfaces
NAT: CDA: GC I.A.7. Identify basic oral and dental anatomy, physiology, and development, including but not limited to: teeth. TOP: BLOOM: Remembering

TRUE/FALSE

1. All anterior teeth have cusps.

ANS: F

All POSTERIOR teeth have cusps; however the only anterior teeth with cusps are canines. In earlier nomenclature, canines were called cuspids. The remaining anterior teeth, the central and lateral incisors, do NOT have cusps.

REF: p. 25 OBJ: To recognize how the functions of teeth determine their shape and size

NAT: CDA: GC I.A.7. Identify basic oral and dental anatomy, physiology, and development, including but not limited to: teeth. TOP: BLOOM: Remembering

2. Cellular cementum has the ability to reproduce itself.

ANS: T

The two types of cementum are cellular and acellular; only the cellular type is capable of reproducing itself. Cellular cementum is confined to the apical third of the root and is able to compensate for the attrition (wear) that occurs on the crown of the tooth throughout life. The cells that produce cementum are called cementocytes.

REF: p. 16 OBJ: To identify the different tissues that compose teeth

NAT: CDA: GC I.A.7. Identify basic oral and dental anatomy, physiology, and development, including but not limited to: teeth. TOP: BLOOM: Remembering

3. Roots of molars can be bifurcated or trifurcated.

ANS: T

While it is true that molars can be bifurcated or trifurcated, this characteristic is dependent on the arch. Maxillary molars are trifurcated, meaning they have three roots; their root is divided into three portions. Mandibular molars are bifurcated; their root is divided into two portions.

REF: p. 14 | p. 172 | p. 183

OBJ: To define single, bifurcated, and trifurcated roots

NAT: CDA: GC I.A.7. Identify basic oral and dental anatomy, physiology, and development, including but not limited to: teeth. TOP: BLOOM: Remembering

4. Mesio-occlusodistal is a location of a point angle.

ANS: F

A mesio-occlusaldistal point angle does not exist. A point angle is the point at which three surfaces meet. The mesial and distal surfaces are separated by too much distance for them to meet at a point with any other surface.

REF: p. 19 OBJ: To name and identify the point angles of teeth

NAT: CDA: GC I.A.7. Identify basic oral and dental anatomy, physiology, and development, including but not limited to: teeth. TOP: BLOOM: Remembering

5. The part of the tooth that shows when someone opens their mouth is the anatomic crown.

ANS: F

The anatomic crown is the entire coronal portion of the tooth that is covered by enamel, regardless of whether it is visible in the mouth or not. Unerupted portions of the crown are considered part of the anatomic crown. By contrast, the clinical crown is only that portion visible above the gingiva, and hence the part visible when someone opens his or her mouth. The clinical crown is also described as that portion of the crown that has erupted.

REF: p. 11 OBJ: To differentiate between clinical and anatomic crowns and roots
NAT: CDA: GC I.A.7. Identify basic oral and dental anatomy, physiology, and development, including but not limited to: teeth. TOP: BLOOM: Remembering

6. Edentulous people may have problems speaking properly.

ANS: T

Teeth are necessary for proper speech and phonetics; therefore those without teeth (edentulous) may have significant problems in this area.

REF: p. 11 OBJ: To identify the different functions of teeth
NAT: CDA: GC I.A.7. Identify basic oral and dental anatomy, physiology, and development, including but not limited to: teeth. TOP: BLOOM: Understanding

7. The lower the root to crown ratio number the more resistance a tooth would have to displacement.

ANS: F

The higher the root to crown ratio number the more resistance to displacement. The root to crown ratio is the length of the root divided by the length of the crown. The root is measured from its apical end to the cervical line. The crown is measured from the cervical line to its most occlusal or incisal part. Almost all anatomic teeth have longer roots than crowns; therefore, the root to crown ratio of anatomic teeth is nearly always at least 1 or more. This ratio affords us a way to compare the resistance to displacement of teeth based on the length of their roots compared with their crowns.

REF: pp. 11-12 OBJ: To understand the significance of the crown/root ratio
NAT: CDA: GC I.A.7. Identify basic oral and dental anatomy, physiology, and development, including but not limited to: teeth. TOP: BLOOM: Understanding

MATCHING

Teeth are comprised of the four tissue types listed below. While examining and treating teeth dental professionals must understand the composition and characteristics of each tissue type. Match the tissue type with the appropriate description.

- a. Enamel
- b. Cementum
- c. Dentin
- d. Pulp

- 1. Has a sensory function
- 2. Outer covering of root
- 3. Hardest mineralized tissue
- 4. Tissue next to pulp

1. ANS: D REF: pp. 13-17 OBJ: To identify the different tissues that compose teeth
NAT: CDA: GC I.A.7. Identify basic oral and dental anatomy, physiology, and development, including but not limited to: teeth. TOP: BLOOM: Remembering
NOT: The pulp has sensory and nourishing functions as well as dentin-reparative capability. Enamel is the most densely mineralized and hardest tissue in the human body. The cementum is a bonelike substance that covers the root and provides a medium for attachment of the tooth to the alveolar bone. Dentin is the tissue that lies next to the pulp, forms the main body of the tooth, and comprises the largest portion of both the crown and root.
2. ANS: B REF: pp. 13-17 OBJ: To identify the different tissues that compose teeth
NAT: CDA: GC I.A.7. Identify basic oral and dental anatomy, physiology, and development, including but not limited to: teeth. TOP: BLOOM: Remembering
NOT: The cementum is a bonelike substance that covers the root and provides a medium for attachment of the tooth to the alveolar bone. Enamel is the most densely mineralized and hardest tissue in the human body. Dentin is the tissue that lies next to the pulp, forms the main body of the tooth, and comprises the largest portion of both the crown and root. The pulp has sensory and nourishing functions as well as dentin-reparative capability.
3. ANS: A REF: pp. 13-17 OBJ: To identify the different tissues that compose teeth
NAT: CDA: GC I.A.7. Identify basic oral and dental anatomy, physiology, and development, including but not limited to: teeth. TOP: BLOOM: Remembering
NOT: Enamel is the most densely mineralized and hardest tissue in the human body. The cementum is a bonelike substance that covers the root and provides a medium for attachment of the tooth to the alveolar bone. Dentin is the tissue that lies next to the pulp, forms the main body of the tooth, and comprises the largest portion of both the crown and root. The pulp has sensory and nourishing functions as well as dentin-reparative capability.
4. ANS: C REF: pp. 13-17 OBJ: To identify the different tissues that compose teeth
NAT: CDA: GC I.A.7. Identify basic oral and dental anatomy, physiology, and development, including but not limited to: teeth. TOP: BLOOM: Remembering
NOT: Dentin is the tissue that lies next to the pulp, forms the main body of the tooth, and comprises the largest portion of both the crown and root. Enamel is the most densely mineralized and hardest tissue in the human body. The cementum is a bonelike substance that covers the root and provides a medium for attachment of the tooth to the alveolar bone. The pulp has sensory and nourishing functions as well as dentin-reparative capability.